



Antiulcer effect of *Helminthostachys zeylanica* (L.) Hook. root extract on ethanol-induced acute gastric lesion in Wistar rats

[Efecto antiulceroso del extracto de raíz de *Helminthostachys zeylanica* (L.) Hook. sobre la lesión gástrica aguda inducida con etanol en ratas Wistar]

Fitrya*, Annisa Amriani, Rennie Puspa Novita, Friscilla Nindita Pamela

Department of Pharmacy, Universitas Sriwijaya, South Sumatera, Indonesia.

*E-mail: fitrya@unsri.ac.id

Abstract

Context: *Helminthostachys zeylanica* is well known as a traditional medicine with various pharmacological activities, including antioxidant and anti-inflammatory. These activities are needed in the treatment of gastric ulcers.

Aims: To evaluate the effectiveness of *H. zeylanica* as an antiulcer agent on acute peptic ulcer.

Methods: The antiulcer effect of the *H. zeylanica* ethanolic extract (100, 200 and 400 mg/kg BW) was studied through ulcer index, physicochemical properties of gastric juice and histopathological analysis in male Wistar rats.

Results: The extract reduces ulcer index, gastric fluid volume, total acidity and increases gastric protection factors such as pH and mucus levels. These results were not significantly different from omeprazole ($p > 0.05$). Photomicrograph analysis showed improvement of membrane structure in extract-treated animals.

Conclusions: *H. zeylanica* extract could be valued as an antiulcer agent.

Keywords: *Helminthostachys zeylanica*; gastric ulcer; ulcer index.

Resumen

Contexto: *Helminthostachys zeylanica* es bien conocida como medicina tradicional con diversas actividades farmacológicas, incluyendo antioxidante y antiinflamatoria. Estas actividades son necesarias en el tratamiento de las úlceras gástricas.

Objetivos: Evaluar la eficacia de *H. zeylanica* como agente antiulceroso en úlcera péptica aguda.

Métodos: Se estudió el efecto antiulceroso del extracto etanólico de *H. zeylanica* (100, 200 y 400 mg/kg de peso corporal) a través del índice de úlcera, propiedades fisicoquímicas del jugo gástrico y análisis histopatológico en ratas Wistar macho.

Resultados: El extracto reduce el índice de úlceras, el volumen de líquido gástrico, la acidez total y aumentar los factores de protección gástrica como el pH y los niveles de moco. Estos resultados no fueron significativamente diferentes del omeprazol ($p > 0,05$). El análisis de fotomicrografía mostró una mejora de la estructura de la membrana en los animales tratados con el extracto.

Conclusiones: El extracto de *H. zeylanica* podría ser valorado como un agente antiulceroso.

Palabras Clave: *Helminthostachys zeylanica*; índice de úlcera; úlcera gástrica.

ARTICLE INFO

Received: December 29, 2021.

Received in revised form: March 6, 2022.

Accepted: March 7, 2022.

Available Online: March 28, 2022.

INTRODUCTION

A peptic ulcer is a lesion on the gastric mucosa characterized by pain in the stomach or bleeding in more severe cases (Bhowmik et al., 2010). According to WHO, deaths from peptic ulcer disease in Indonesia are approximately 25 559 or 1.50% of the total deaths, ranking fourth in the world (Health Rankings, 2020). In Indonesia, the prevalence is 6-15% of the total population, specifically those between 20-50 years with a peak age of 50-60 years (Health of Ministry, 2019).

There are three main causes of peptic ulcer etiology: non-steroidal anti-inflammatory drugs (NSAIDs), *Helicobacter pylori* infection, and acid hypersecretion conditions such as Zollinger-Ellison syndrome (Aslam et al., 2020; Raish et al., 2021). Meanwhile, the pathophysiology of ulcers is caused by an imbalance between aggressive factors such as hydrochloric acid and pepsin, together with defensive factors such as mucus and bicarbonate (Raish et al., 2021). Synthetic materials, including cytoprotectives, are often used in peptic ulcer therapy, one of which is omeprazole. However, omeprazole causes some side effects, including diarrhea, nausea, vomiting, abdominal pain, and numbness in the extremities, among others. Therefore, there is a need to consider safer alternative drugs in herbal medicines (Park et al., 2019).

Helminthostachys zeylanica (L.) Hook. (family *Ophioglossaceae*), known as Tunjuk Langit in Indonesia, is biologically rich in potential flavonoids such as ugonin A-Z (Chen et al., 2003; Huang et al., 2003; 2017) and ugonstilben, which can be used as an alternative medicine for peptic ulcers because of their antioxidants and anti-inflammatory activities. Previous studies on the pharmacological effects of *H. zeylanica* extracts include hepatoprotective (Suja et al., 2004; Wu et al., 2018), cytotoxic and antioxidant (Huang et al., 2003), anti-hyperuricemia (Fitrya and Muharni, 2014), anti-inflammatory (Hsieh et al., 2016; Wu et al., 2017b), anti-melanogenesis (Yamauchi et al., 2015), antiosteoporosis (Huang et al., 2017), anti-acute lung inflammation (Liou et al., 2017), suppressive vascular abnormalities (Pan et al., 2018), antisteatosis (Chang et al., 2019), and antidiabetic (Ridhasya et al., 2019). However, there are no studies on the potential of its extract as an antiulcer. Therefore, this study aims to identify the potential of *H. zeylanica* root ethanolic extract as an anti-ulcerous in animals induced with acute gastric lesions and determine the gastric histopathology of animals.

MATERIAL AND METHODS

Materials

H. zeylanica roots were collected from the Musi Banyuasin area, South Sumatra Indonesia (3°13'07.3"S 104°38'43.8"E) in October 2019 and identified in Indonesian Institute of Science with No. 106/IPH.06/HM/I/2019. The specimen was deposited in the Biology Department, University of Sriwijaya. Other materials are ethanol absolute (Merck®), sodium carboxymethylcellulose (Na-CMC) (Brataco®), NaOH (Merck®), omeprazole (Dexa Medica®), Alcian blue staining (Sigma Aldrich).

Preparation of ethanol extract from *H. zeylanica* root

Preparation of the sample of *H. zeylanica* begins with wet sorting, drying and dry sorting. Drying was carried out using an oven at a temperature of 40°C to constant weight. The dried *H. zeylanica* was ground using the herbal grinder (MS-ML100) and sieved with a fineness degree of 30 mesh.

H. zeylanica root was subjected to a process of extraction by maceration. A total of 1 kg of its powder was macerated with 96% ethanol (48 h). The maceration process was carried out four times until the solvent appeared colorless. Subsequently, total macerate was evaporated in a rotary evaporator (Buchi®) at a temperature of 70°C until a thick extract was obtained. The extract was stored in the refrigerator at 4°C before use.

Determination of total flavonoids

A total of 20 mg of *H. zeylanica* extract was dissolved in 10 mL of absolute ethanol to obtain a concentration of 2 mg/mL as stock solution. A total of 0.1 mL of 10% AlCl₃, 0.1 mL of 1 M sodium acetate, and 2.8 mL of distilled water were added to 0.5 mL of stock solution, then incubated for 30 min. The total flavonoids in the extract were determined using the spectrometric method, while the standard curve was from solutions of quercetin 20, 30, 40, 50, and 60 ppm. Furthermore, extract absorbance was measured at a maximum wavelength (λ) of 440 nm, and the flavonoid levels were measured based on the relation between absorbance and concentration on the standard curve. The total flavonoid content was expressed as the quercetin equivalent (QE) per gram of extract (Pontis et al., 2014).

Antiulcer effect test

In this study, 30 male Wistar rats weighing 180-200 g were used, and the ethics of using animals has received approval from the Health Polytechnic of Pa-

lembang with No: 533 KEPK/Adm2/XII/2020. The rats were climatized for one week under adequate lighting (12 h of light) and room temperature of 22°C. Food and drink were provided *ad libitum*, and the animals were randomly assigned to 6 groups, namely normal and negative groups that received 1 mL of 0.5% Na-CMC orally. Furthermore, the positive group received 20 mg/kg BW orally of omeprazole, and the test group received TL extract at doses of 100, 200, and 400 mg/kg BW for 14 days by oral.

After 14 days of treatment, the rats fasted for 24 h, and on the 15th day, all groups were induced with absolute ethanol 1 mL/200 g BW orally except the normal group. Meanwhile, two hours after induction, the animals were sacrificed by cervical dislocation, and surgery was continued. Rats were dissected to take gastric organs and observed macroscopically by examining the characteristics of color, size, and severity of the lesions. Gastric fluid was used to analyze antiulcer parameters, namely volume, pH, total acidity, and gastric wall mucus, while a photomicrograph of gastric tissue was further taken for histopathological analysis (Jincy and Sunil, 2020; Najini et al., 2018; Zakaria et al., 2015).

Measurement of ulcer area and ulcer index

The lesion area was observed macroscopically, and images were taken with a digital camera (Canon® Japan), and the gastric ulcer area was quantified using MacBioPhotonics image J program (Najini et al., 2018). Furthermore, the ulcer area was measured by the ulcer score parameter. Referring to Hina (2013), ulcer scores were classified from 0-3 where 0 = normal to 3 (lesion size > 3 mm). Meanwhile, the Ulcer Index (UI) was calculated by adding the mean number of ulcers + mean ulcer severity score + percentage of rats with ulcers divided by 10 (Hina et al., 2013; Jincy and Sunil, 2020; Maria et al., 2015). The percentage of inhibition (I%) was calculated by the equation [1] (Al-Batran et al., 2013; Maria et al., 2015; Trinovita and Fatmaria, 2020).

$$\text{Ulcer inhibition (\%)} = \frac{\text{UI control} - \text{UI treated}}{\text{UI control}} \times 100\% \quad [1]$$

Determination of physicochemical gastric fluids properties

The entire gastric fluid was removed and collected in a graduated centrifugation tube, which was recorded as the volume of gastric fluid. It was centrifuged at 2500 rpm for 10 min, and the supernatant was determined with a pH meter and recorded as gastric fluid pH (Kandhare et al., 2012). The total acidity was determined by the titration method. A total of 1 mL of the supernatant was diluted with distilled water to a volume of 10 mL and titrated with 0.01 N NaOH with

phenolphthalein as an indicator. The formation of pink color indicated the endpoint of the titration, and the total acidity value was expressed in mEq/L (Hina et al., 2013; Jincy and Sunil, 2020; Zakaria et al., 2015).

Gastric wall mucus or mucin levels were determined by a spectrometer, where using an Alcian blue was used as a complexing agent. The mucin content was proportional to Alcian blue (AB) amount, which formed a complex with mucus. The absorbance AB was measured with a spectrometer at 580 nm, and the Alcian blue extract quantity per gram of tissue was calculated from standard curves (Ijioma et al., 2018; Raish et al., 2021; Saremi et al., 2019; Zakaria et al., 2015; Zhou et al., 2020)

Gastric histopathological observations

The gastric organs were fixed with 10% formalin buffer for 24 h and the tissue was dehydrated with alcohol. Subsequently, the tissue was made of paraffin blocks and cut with a thickness of 5 µm using a microtome. The incisions were attached to a slide, which was stained with hematoxylin and eosin (H&E) staining (Al-Batran et al., 2013; Laloo et al., 2013; Maria et al., 2015).

Statistical analysis

Normality test using Shapiro-Wilk to determine the distribution of data. The data were processed using SPSS 26 and shown as mean ± SD. Furthermore, the variance was analyzed using a one-way ANOVA model with a 95% confidence level ($p < 0.05$), which stated that the data were normally distributed, then continued with Tukey's *post-hoc* test to find out the differences between groups. Differences between groups were considered statistically significant if $p < 0.05$.

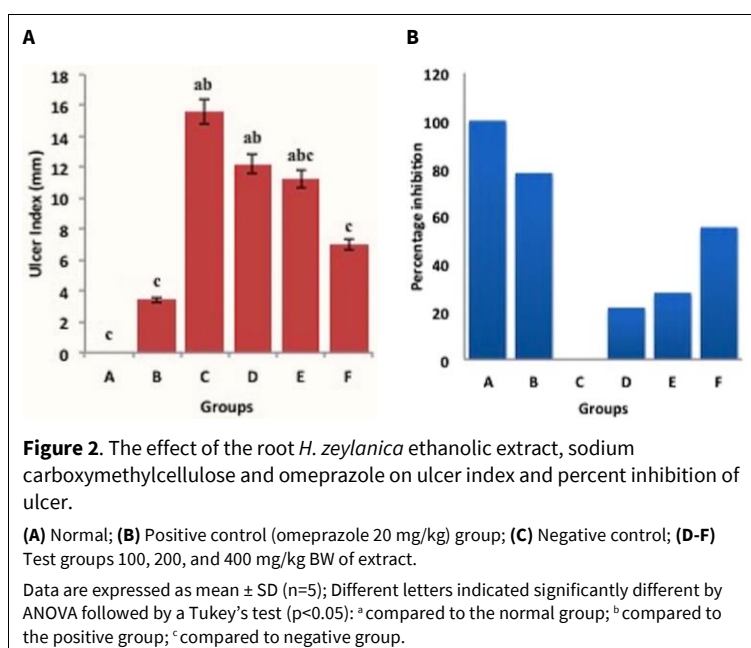
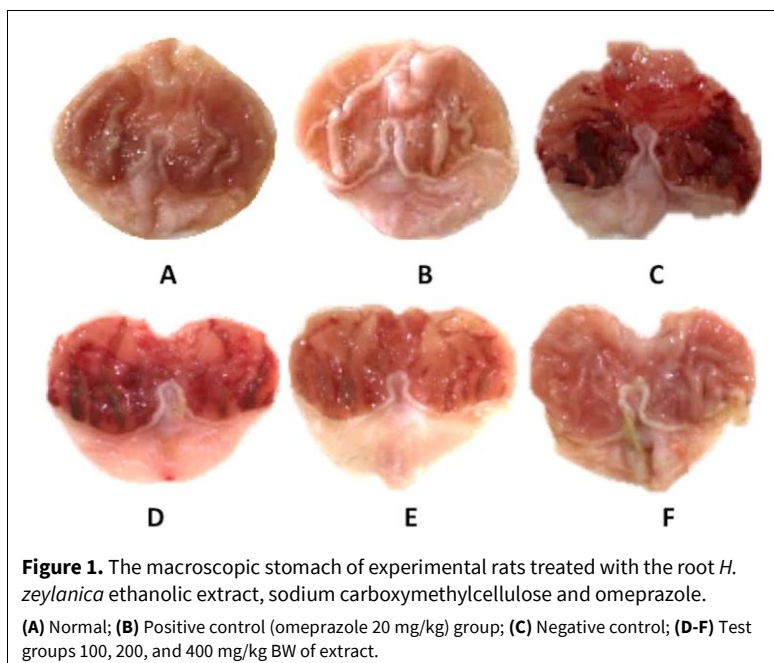
RESULTS

Total flavonoids of *H. zeylanica* root ethanolic extract

The total flavonoids in the ethanol extract of the *H. zeylanica* root were 51.12 mg in 1 g of the extract (5.11%).

Antiulcer effects of *H. zeylanica* root ethanolic extract

Based on the evaluation of the lesion area, it was found that the stomach of the normal and positive control group showed an ulcer score of 0. The negative control group showed the lesion with the highest severity, namely the ulcer score of 3. The test groups showed that the mean ulcer scores were 3, 2 and 0.5, respectively, for doses 100, 200 and 400 mg/kg BW. Based on the macroscopic observations, the heaviest



lesions occurred in the group with a dose of 100 mg/kg BW. In the 200 mg/kg BW dose group, the severity of the lesions decreased significantly ($p < 0.05$), meanwhile, there was a slight redness and no hemorrhagic stress in the 400 mg/kg BW (Fig. 1). This indicated that the *H. zeylanica* root extract at a 400 mg/kg BW dose showed an anti-ulcerative effect.

The ulcer index value and the average inhibition percentage are shown in Fig. 2.

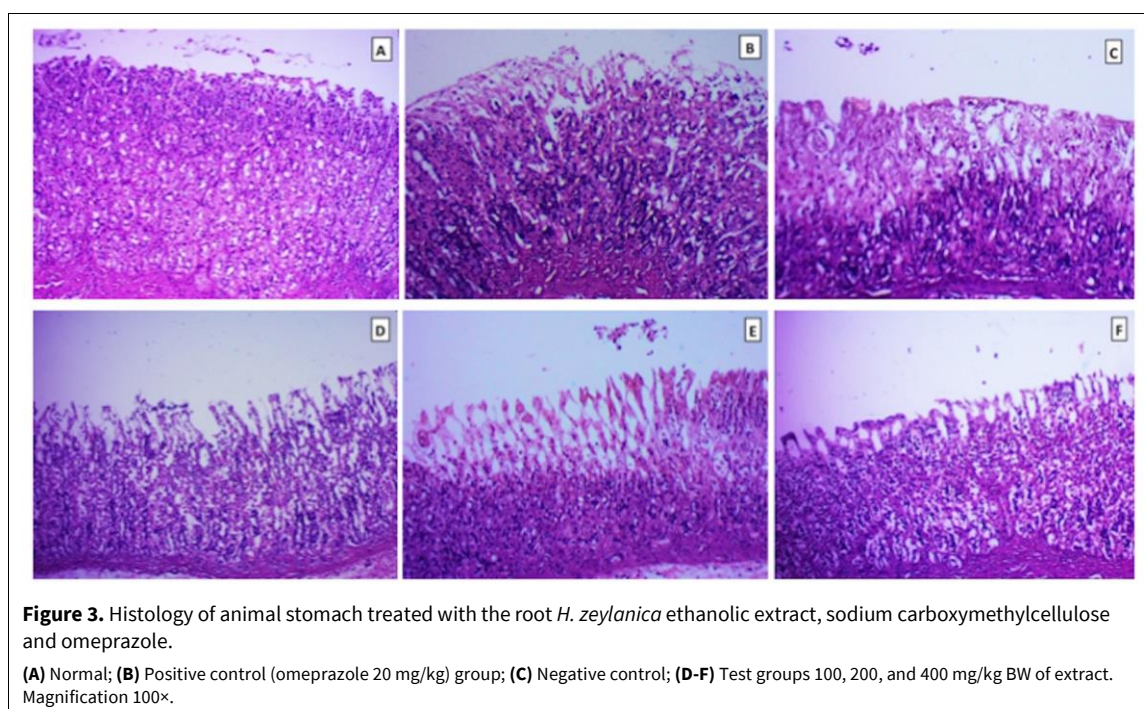
H. zeylanica extract at a dose of 100 mg/kg BW had an ulcer index (UI), which was not significantly different from the negative control ($p > 0.05$). While at

doses of 200 and 400 mg/kg BW there was a significant difference with the negative control ($p < 0.05$), but only the 400 mg/kg BW group was similar to the positive and normal groups ($p > 0.05$). Although the ulcer index in the 200 mg/kg BW group did not show a statistically significant difference with the 400 mg/kg BW group ($p = 0.984$), they had a different percentage of inhibition. This is supported by the macroscopic appearance of the stomach, which shows that the 400 mg/kg BW group was better at preventing ulcers. This indicated that the anti-ulcerative effect of the ethanolic extract of *H. zeylanica* root was dose-dependent.

Table 1. The effect of the root *H. zeylanica* ethanolic extract on physicochemical properties of gastric fluid.

Groups	Volume (mL) \pm SD	pH \pm SD	Total acidity (mEq/L) \pm SD	Mucin content (μ g AB/g tissue)
Normal control (0.5% Na-CMC)	0.50 \pm 0.38 ^c	5.00 \pm 0.00	10.00 \pm 0.00 ^c	296 \pm 20.00 ^c
Omeprazole (20 mg/kg)	0.80 \pm 0.20 ^c	5.00 \pm 1.00	25.00 \pm 5.00 ^c	313 \pm 15.00 ^c
Negative control (0.5% Na-CMC)	3.33 \pm 0.76 ^{ab}	3.33 \pm 1.53	38.33 \pm 0.71 ^{ab}	220 \pm 20.00 ^{ab}
Extract (100 mg/kg)	3.92 \pm 0.38 ^{abc}	3.67 \pm 0.57	29.67 \pm 4.16 ^c	244 \pm 40.00 ^{ac}
Extract (200 mg/kg)	1.83 \pm 0.29 ^{abc}	4.00 \pm 1.73	26.00 \pm 0.76 ^c	260 \pm 10.00 ^b
Extract (400 mg/kg)	1.33 \pm 0.58 ^c	5.00 \pm 1.52	11.33 \pm 1.53 ^c	303 \pm 20.00 ^c

Data are expressed as mean \pm SD (n=5); Different letters indicated the significantly different by ANOVA followed by a Tukey's test ($p < 0.05$): ^a compared to the normal group; ^b compare to the positive group; ^c compare to the negative group. Na-CMC: Sodium carboxymethylcellulose.



Antiulcer parameter

In all test groups, volume, total acidity, and mucin levels (except the medium-dose group) showed significant differences with the negative control ($p < 0.05$), while the high dose group was not different from the normal and the omeprazole groups ($p > 0.05$). Meanwhile, the results of the gastric fluid analysis are shown in Table 1.

The gastric pH of the test group was not significantly different from normal, positive, and negative controls ($p > 0.05$), but the pH of all groups of extract doses increased compared to negative controls. Similarly, there was no significant difference in pH between the test groups.

Histopathology of normal and positive controls showed no necrosis on the surface of the epithelial cells, while the negative control showed irregularities

in the gastric mucosal epithelium with necrosis penetrating the sub-mucosa. The histopathological of the 100 mg/kg extract gave moderate damage to the epithelial cell surface with necrotic lesions penetrating the sub-mucosa. The damage was lighter in the medium-dose group, where the necrosis did not penetrate the sub-mucosa. However, the high dose group showed no damage and necrosis on the surface of the sub-mucosal epithelial cells. The histopathological description of the rat stomach from each group is shown in Fig. 3.

DISCUSSION

This study was conducted to determine the potential of *H. zeylanica* extracts as an antiulcer due to the chemical constituents. Presently, there are more than 20 flavonoid compounds have been identified as ugonin A-Z and ugonstilben A-C from *H. zeylanica*

roots (Chen et al., 2014; Huang et al., 2009; 2017; Su et al., 2016). The quantitative analysis of total flavonoid was 51.12 mg/g extract. A previous study by Wu et al. (2017b) showed that the levels of several constituents of the extract, such as quercetin, ugonin J, and ugonin M in the extract, were 0.056, 0.112, and 0.277 mg/g, respectively (Wu et al., 2017b).

Macroscopic observations showed that absolute ethanol causes gastric ulcers in rats, characterized by spot ulcers and heavy bleeding. In addition, it also increases the volume of gastric acid through the histamine release mechanism, and a factor that plays in this damage is the loss of the protective effect of prostacyclin (PGI₂) (Abdulla et al., 2010). The ulcers are caused by the erosion of the epithelial membrane and damage to the gastric mucosal barrier due to the administration of absolute ethanol, which burst the blood vessels (de Souza et al., 2019; Hamed et al., 2015; Zhang et al., 2019). This is indicated by the ulcer score of the negative control group being the highest. Meanwhile, the group receiving *H. zeylanica* extract showed a decrease in the lesion score as the dose increased. The observations also showed that the *H. zeylanica* extract at a dose of 400 mg/kg prevented ulcers, equivalent to the ability of omeprazole (20 mg/kg). This is in accordance with the ulcer index value of this group was not significantly different from the omeprazole group ($p > 0.05$). In addition, the ability of *H. zeylanica* extract in preventing ulcer disease is thought to be caused by its antioxidant and anti-inflammatory activity.

There was no significant difference between the pH of all test groups; however, based on volume analysis and total acidity, the high dose group showed the ability to inhibit HCl secretion, which was similar to the omeprazole ($p > 0.05$). The normal control pH was different from the normal gastric pH, which should have a more acidic range from 1 to 3.5. This was because there are still food residues in the stomach of animals that can increase the pH to 5.5-7 (Singh and Gallier, 2014). An increase in the dose of the extract significantly reduces the volume and total acidity of gastric fluid and increases the mucin secretion. This showed that *H. zeylanica* extract could prevent peptic ulcers because agents that increase mucus secretion and decrease acid secretion are potentially antiulcer drugs (Ahmad et al., 2013; Jincy and Sunil, 2020). The omeprazole group was the best in suppressing gastric acid secretion and gastric fluid volume because it irreversibly inhibits H⁺K⁺ATPase in gastric parietal cells (Adefisayo et al., 2017; Yasin et al., 2020).

The *H. zeylanica* roots are known to contain flavonoids such as quercetin and ugonin that are active as antioxidants (Huang et al., 2003) and anti-

inflammatory (Hsieh et al., 2016; Wu et al., 2017b). Quercetin can scavenge free radicals such as superoxide anions, peroxy, and hydroxyl radicals (Abourehab et al., 2015; Yasin et al., 2020), which shows gastroprotective activity through reduced lipid peroxidation, mast cells, and increased activity of antioxidant enzymes (Jincy and Sunil, 2020). Moreover, ugonin M (Wu et al., 2018), ugonin V, W, Y and ugonin J-R, and ugonstilben have been reported to inhibit nitric oxide (NO) production with IC₅₀ values of 6.2–10.1 μ M (Huang et al., 2017). One neougonin A compound also showed inhibitory activity of lipopolysaccharide (LPS)-induced NO production in RAW264.7 cells with an IC₅₀ value of 3.32 μ M (Cao et al., 2016; Su et al., 2016). The NO is a species that reacts with various reactive oxygen species (ROS) to form peroxynitrite, which causes a cytotoxic effect on neutrophils and exacerbates lipid peroxidation (Beckman et al., 1990; Wu et al., 2018). Inhibition of NO production, in turn, inhibits lipid peroxidation. Since antioxidants work by neutralizing ROS, there is a balance between aggressive and defensive factors (Hsieh et al., 2016; Huang et al., 2003). Ugonin M was able to suppress pro-inflammatory cytokines such as tumor necrosis factor- α (TNF- α), interleukin-6 (IL-6), and IL-1 β , together with proteins such as inducible nitric oxide synthase (iNOS) and cyclooxygenase-2 (COX-2). Furthermore, it also increased the production of antioxidant enzymes, namely superoxide dismutase (SOD), glutathione peroxidase (GPx), and catalase (CAT) (Huang et al., 2009; Wu et al., 2018, 2017a). The SOD works to reduce injury in many disease processes (Beckman et al., 1990; Zakaria et al., 2015). One of the targets of superoxide is the production of NO by the endothelium, macrophages, neutrophils (Beckman et al., 1990). Ugonin M can also decrease COX-2, which is the dominant cyclooxygenase in the inflammatory response and contributes significantly to prostaglandin synthesis in the ulcer area (Fang et al., 2008; Halter et al., 2001). Thus, ugonin M can effectively reduce free radical damage and lipid peroxidation, reducing inflammation. (Wu et al., 2018).

Based on this study, the *H. zeylanica* extract was able to increase mucus secretion; therefore, it is cytoprotective (de Olinda et al., 2008). Moreover, the main target of peptic ulcer therapy is to improve the quality and quantity of mucus and inhibit acid secretion (Ijioma et al., 2018). Mucus is composed of water and glycoprotein, preventing ulcer formation and increasing gastric juice buffer (de Souza et al., 2019; Halim et al., 2017).

Histopathological evaluation of gastric tissue was carried out to determine the ability of the extract to recover the damage caused by ethanol. This histo-

pathological observation led to a morphological description of the damage in form of necrosis in the stomach of rats, which changes the normal structure of the gastric mucosa (Laloo et al., 2013). The photomicrograph of the stomach of normal group rats showed regularity in which the gastric epithelium appeared regular and intact. The positive control group showed no necrosis on the surface of the epithelial cells because the omeprazole inhibits the proton pump that binds covalently to H⁺K⁺ATPase, thereby blocking acid secretion into the gastric mucosa (Yasin et al., 2020). A negative control photomicrograph showed irregularities in the epithelial layer, where necrosis damage to the gastric mucosa penetrates the sub-mucosa. This occurred because absolute ethanol causes impaired mucosal integrity, which triggered the release of inflammatory mediators such as histamine and leukotriene's in the gastric mucosa (de Souza et al., 2019; Guzmán-Gómez et al., 2018).

The antiulcer activity shown by the extract group is due to the antioxidant and anti-inflammatory activity of the phytochemical components. Ugonin M is an important component of the *H. zeylanica* roots with a role in overcoming inflammation. According to (Wu et al., 2018), ugonin M works to overcome inflammation through a down-regulation system where it inhibits the expression of NF-κB, which functions in the synthesis of pro-inflammatory cytokines (such as TNF-, IL-6, and IL-1β) and the expression of iNOS and COX-2. Meanwhile, the decrease in the levels of NF-κB led to the reduction in the levels of cytokines and expression of iNOS and COX-2. This showed that the anti-inflammatory and antioxidant activity exhibited by quercetin, ugonin, and ugonstilben from *H. zeylanica* extract can produce an antiulcer effect in acute gastric lesions in experimental animals.

CONCLUSION

The analysis of antiulcer and histopathological parameters showed that *H. zeylanica* root ethanol extract has the potential as an antiulcer agent in acute gastric lesions. In addition, the antiulcer activity could be produced by flavonoid chemical components, which worked through antioxidant and anti-inflammatory activities.

CONFLICT OF INTEREST

The authors declare no conflicts of interest.

ACKNOWLEDGMENTS

The authors are grateful to the head of the Pharmacology Laboratory of Sriwijaya University and the staff for supporting this study. This research did not receive any specific

grant from funding agencies in the public, commercial, or not-for-profit sectors.

REFERENCES

- Abdulla MA, Ahmed KAA, Al-Bayaty FH, Masood Y (2010) Gastroprotective effect of *Phyllanthus niruri* leaf extract against ethanol-induced gastric mucosal injury in rats. *African J Pharm Pharmacol* 4(5): 226–230.
- Abourehab MAS, Khaled KA, Sarhan HAA, Ahmed OAA (2015) Evaluation of combined famotidine with quercetin for the treatment of peptic ulcer: *In vivo* animal study. *Drug Des Devel Thee* 9: 2159–2169.
- Adefisayo MA, Akomolafe RO, Akinsomisoye SO, Alabi QK, Ogundipe OL, Omole JG, Olamilosoye KP (2017) Gastro-protective effect of methanol extract of *Vernonia amygdalina* (Del.) leaf on aspirin-induced gastric ulcer in Wistar rats. *Toxicol Reports* 4: 625–633.
- Ahmad A, Gupta G, Afzal M, Kazmi I, Anwar F (2013) Antiulcer and antioxidant activities of a new steroid from *Morus alba*. *Life Sci* 92: 202–210.
- Al-Batran R, Al-Bayaty F, Al-Obaidi MMJ, Abdualkader AM, Hadi HA, Ali HM, Abdulla MA (2013) *In vivo* antioxidant and antiulcer activity of *Parkia speciosa* ethanolic leaf extract against ethanol-induced gastric ulcer in rats. *PLoS One* 8(5): e64751.
- Aslam S, Tahir MA, Abbasi MSA (2020) Gastro - Protective effect of *Grewia optiva* (Dhamna) leaf extract on ethanol induced gastric ulcer in rats. *Asian J Res Reports Gastroenterol* 4(1): 19–26.
- Beckman JS, Beckman TW, Chen J, Marshall PA, Freeman BA (1990) Apparent hydroxyl radical production by peroxynitrite: Implications for endothelial injury from nitric oxide and superoxide. *Proc Natl Acad Sci USA* 87: 1620–1624.
- Bhowmik D, Chiranjib, Tripathi KK, Pankaj, Kumar KPS (2010) Recent trends of treatment and medication peptic ulcerative disorder. *Int J PharmTech Res* 2(1): 970–980.
- Cao L, Li R, Chen X, Xue Y, Liu D (2016) Neougonin A inhibits lipopolysaccharide-induced inflammatory responses via downregulation of the NF-κB signaling pathway in RAW 264.7 macrophages. *Inflammation* 39(6): 1939–1948.
- Chang TC, Chiang H, Lai YH, Huang YL, Huang HC, Liang YC, Liu HK, Huang C (2019) *Helminthostachys zeylanica* alleviates hepatic steatosis and insulin resistance in diet-induced obese mice. *BMC Complement Altern Med* 19: 368.
- Chen CC, Huang YL, Yeh PY, Ou JC (2003) Cyclized geranyl stilbenes from the rhizomes of *Helminthostachys zeylanica*. *Planta Med* 69: 964–967.
- Chen CY, Liaw CC, Chen YH, Chang WY, Chung PJ, Hwang TL (2014) A novel immunomodulatory effect of ugonin U in human neutrophils via stimulation of phospholipase C. *Free Radic Biol Med* 72: 222–231.
- de Olinda TM, Lemos TLG, Machado LL, Rao VS, Santos FA (2008) Quebrachitol-induced gastroprotection against acute gastric lesions: Role of prostaglandins,

- nitric oxide and K⁺ATP channels. *Phytomedicine* 15: 327–333.
- de Souza MC, Vieira AJ, Beserra FP, Pellizzon CH, Nóbrega RH, Rozza AL (2019) Gastroprotective effect of limonene in rats: Influence on oxidative stress, inflammation and gene expression. *Phytomedicine* 53: 37–42.
- Fang SC, Hsu CL, Yen GC (2008) Anti-inflammatory effects of phenolic compounds isolated from the fruits of *Artocarpus heterophyllus*. *J Agric Food Chem* 56: 4463–4468.
- Fitrya, Muharni (2014) An antihyperuricemia effect of ethanol extract of tunjuk langit rhizome (*Helminthostachys zeylanica* Linn Hook) on Swiss male mice. *Tradis Med J* 19(1): 14–18.
- Guzmán-Gómez O, García-Rodríguez RV, Quevedo-Corona L, Pérez-Pastén-Borja R, Rivero-Ramírez NL, Ríos-Castro E, Pérez-Gutiérrez S, Pérez-Ramos J, Chamorro-Cevallos GA (2018) Amelioration of ethanol-induced gastric ulcers in rats pretreated with phycobiliproteins of *Arthrospira (Spirulina) maxima*. *Nutrients* 10: 763.
- Halim SZ, Zakaria ZA, Omar MH, Mohtarrudin N, Wahab IRA, Abdullah MNH (2017) Synergistic gastroprotective activity of methanolic extract of a mixture of *Melastoma malabathricum* and *Muntingia calabura* leaves in rats. *BMC Complement Altern Med* 17: 488.
- Halter F, Tarnawski AS, Schmassmann A, Peskar BM (2001) Cyclooxygenase 2 - Implications on maintenance of gastric mucosal integrity and ulcer healing: Controversial issues and perspectives. *Gut* 49: 443–453.
- Hamed S, Arian AA, Farzaei MH (2015) Gastroprotective effect of aqueous stem bark extract of *Ziziphus jujuba* L. against HCl/Ethanol-induced gastric mucosal injury in rats. *J Tradit Chin Med* 35(6): 666–670.
- Health of Ministry, Indonesia (2019) Profil Kesehatan Indonesia 2018. Kementerian Kesehatan Republik Indonesia, Jakarta.
- Health Rankings, WHO (2020) World Health Rankings. World Life Expect. Com. URL <https://www.worldlifeexpectancy.com/indonesia-peptic-ulcer-disease>. [Consulted 21 March 2021]
- Hina K, Safhi MM, Agarwal M, Gyas K, Govind M (2013) Antiulcer activity of seed extracts of *Gynocardia odorata* Roxb. on pylorus ligation and indomethacin induced gastric lesions in albino rats. *Int J Dev Res* 3(5): 49–54.
- Hsieh HL, Yang SH, Lee TH, Fang JY, Lin CF (2016) Evaluation of anti-inflammatory effects of *Helminthostachys zeylanica* extracts via inhibiting bradykinin-induced MMP-9 expression in brain astrocytes. *Mol Neurobiol* 53: 5995–6005.
- Huang YC, Hwan TL, Chang CS, Yang YL, Shen CN, Liao WY, Chen SC, Liaw CC (2009) Anti-inflammatory flavonoids from the rhizomes of *Helminthostachys zeylanica*. *J Nat Prod* 72(7): 1273–1278.
- Huang YL, Shen CC, Shen YC, Chiou WF, Chen CC (2017) Anti-inflammatory and antiosteoporosis flavonoids from the rhizomes of *Helminthostachys zeylanica*. *J Nat Prod* 80(2): 246–253.
- Huang YL, Yeh PY, Shen CC, Chen CC (2003) Antioxidant flavonoids from the rhizomes of *Helminthostachys zeylanica*. *Phytochemistry* 64: 1277–1283.
- Ijioma SN, Nwaogazi EN, Nwankwo AA, Oshilonya H, Ekeleme CM, Oshilonya LU (2018) Histological exhibition of the gastroprotective effect of *Moringa oleifera* leaf extract. *Comp Clin Path* 27: 327–332.
- Jincy J, Sunil C (2020) Exploring antiulcer and anti-inflammatory activities of methanolic leaves extract of an Indian mistletoe *Helicantes elasticus* (Desv.) Danser. *South African J Bot* 133: 10–16.
- Kandhare AD, Kumar VS, Adil M, Rajmane AR, Ghosh P, Bodhankar SL (2012) Investigation of gastro protective activity of *Xanthium strumarium* L. by modulation of cellular and biochemical marker. *Orient Pharm Exp Med* 12: 287–299.
- Laloo D, Prasad SK, Krishnamurthy S, Hemalatha S (2013) Gastroprotective activity of ethanolic root extract of *Potentilla fulgens* Wall. ex Hook. *J Ethnopharmacol* 146: 505–514.
- Liou CJ, Huang YL, Huang WC, Yeh KW, Huang TY, Lin CF (2017) Water extract of *Helminthostachys zeylanica* attenuates LPS-induced acute lung injury in mice by modulating NF- κ B and MAPK pathways. *J Ethnopharmacol* 199: 30–38.
- Maria MS, Devarakonda S, Kumar AT, Balakrishnan N (2015) Anti-ulcer activity of ethanol extract of *Parkia speciosa* against indomethacin induced peptic ulcer in Albino rats. *Int J Pharm Sci Res* 6(2): 895–902.
- Najini R, Bachri MS, Yuliani S (2018) The gastroprotective effects of *Canna edulis* Ker. tuber starch on peptic ulcer and the histopathological profile of rat stomach. *Pharmaciana* 8(1): 43–52.
- Pan CH, Li PC, Chien YC, Yeh WT, Liaw CC, Sheu MJ, Wu CH (2018) Suppressive activities and mechanisms of ugonin J on vascular smooth muscle cells and balloon angioplasty-induced neointimal hyperplasia. *Phyther Res* 32(2): 312–320.
- Park JU, Kang JH, Rahman MAA, Hussain A, Cho JS, Lee YI (2019) Gastroprotective effects of plants extracts on gastric mucosal injury in experimental Sprague-Dawley rats. *Biomed Res Int* 2019: 8759708.
- Pontis JA, da Costa LAMA, da Silva SJR, Flach A (2014) Color, phenolic and flavonoid content, and antioxidant activity of honey from Roraima, Brazil. *Food Sci Technol* 34(1): 69–73.
- Raish M, Shahid M, Bin Jordan YA, Ansari MA, Alkharfy KM, Ahad A, Abdelrahman IA, Ahmad A, Al-Jenoobi FI (2021) Gastroprotective effect of sinapic acid on ethanol-induced gastric ulcers in rats: Involvement of Nrf2/HO-1 and NF- κ B signaling and antiapoptotic role. *Front. Pharmacol* 12: 622815.
- Ridhasya FE, Teruna HY, Hendra R, Almurdani M (2019) Natural antidiabetic of tunjuk langit (*Helminthostachys zeylanica*) rhizome extracts. *Pharmacol Clin Pharm Res* 4: 18–21.
- Saremi K, Rad SK, Tayeby F, Abdulla MA, Karimian H, Majid NA (2019) Gastroprotective activity of a novel Schiff base derived dibromo substituted compound

- against ethanol-induced acute gastric lesions in rats. *BMC Pharmacol Toxicol* 20: 13.
- Singh H, Gallier S (2014) Processing of Food Structures in the Gastrointestinal Tract and Physiological Responses, in: *Food Structures, Digestion and Health*. Utrecht, Netherlands, pp. 51–81.
- Su LH, Li YP, Li HM, Dai WF, Liu D, Cao L, Li RT (2016) Anti-inflammatory prenylated flavonoids from *Helminthostachys zeylanica*. *Chem Pharm Bull* 64(5): 497–501.
- Suja SR, Latha PG, Pushpangadan P, Rajasekharan S (2004) Evaluation of hepatoprotective effects of *Helminthostachys zeylanica* (L.) Hook against carbon tetrachloride-induced liver damage in Wistar rats. *J Ethnopharmacol* 92: 61–66.
- Trinovita E, Fatmaria F (2020) Evaluation of gastroprotective activity of cemot leaves (*Passiflora foetida* L.) extracted by ultrasonic assisted extraction (UAE) against ethanol-induced gastric lesions in rats. *Trad Med J* 25(2): 110–117.
- Wu KC, Ho YL, Kuo YH, Huang SS, Huang GJ, Chang YS (2018) Hepatoprotective effect of ugonin M, A *Helminthostachys zeylanica* constituent, on acetaminophen-induced acute liver injury in mice. *Molecules* 23: 2420.
- Wu KC, Huang SS, Kuo YH, Ho YL, Yang CS, Chang YS, Huang GJ (2017a) Ugonin M, a *Helminthostachys zeylanica* constituent, prevents LPS-induced acute lung injury through TLR4-mediated mapk and nf-kb signaling pathways. *Molecules* 22: 573.
- Wu KC, Kao CP, Ho YL, Chang YS (2017b) Quality control of the root and rhizome of *Helminthostachys zeylanica* (Daodi-Ugon) by HPLC using quercetin and ugonins as markers. *Molecules* 22: 1115.
- Yamauchi K, Mitsunaga T, Itakura Y, Batubara I (2015) Extracellular melanogenesis inhibitory activity and the structure-activity relationships of ugonins from *Helminthostachys zeylanica* roots. *Fitoterapia* 104: 69–74.
- Yasin H, Tariq F, Sameen A, Ahmad N, Manzoor MF, Yasin M, Tariq T, Iqbal MW, Ishfaq B, Mahmood S, Siddeeg A (2020) Ethanolic extract of okra has a potential gastroprotective effect on acute gastric lesions in Sprague Dawley rats. *Food Sci Nutr* 8(12): 6691–6698.
- Zakaria ZA, Balan T, Mamat SS, Mohtarrudin N, Kek TL, Salleh MZ (2015) Mechanisms of gastroprotection of methanol extract of *Melastoma malabathricum* leaves. *BMC Complement Altern Med* 15: 135.
- Zhang C, Gao F, Gan S, He Y, Chen Z, Liu X, Fu C, Qu Y, Zhang J (2019) Chemical characterization and gastroprotective effect of an isolated polysaccharide fraction from *Bletilla striata* against ethanol-induced acute gastric ulcer. *Food Chem Toxicol* 131: 110539.
- Zhou D, Yang Q, Tian T, Chang Y, Li Y, Duan LR, Li H, Wang SW (2020) Gastroprotective effect of gallic acid against ethanol-induced gastric ulcer in rats: Involvement of the Nrf2/HO-1 signaling and anti-apoptosis role. *Biomed Pharmacother* 126: 110075.

AUTHOR CONTRIBUTION:

Contribution	Fitrya	Annisa A	Rennie PN	Friscilla NP
Concepts or ideas	x			
Design	x			
Definition of intellectual content	x	x	x	x
Literature search	x	x	x	x
Experimental studies	x			x
Data acquisition	x	x	x	x
Data analysis	x	x	x	x
Statistical analysis	x	x	x	x
Manuscript preparation	x	x	x	x
Manuscript editing	x	x	x	x
Manuscript review	x	x	x	x

Citation Format: Fitrya, Annisa A, Rennie PN, Friscilla NP (2022) Antiulcer effect of *Helminthostachys zeylanica* (L.) Hook. root extract on ethanol-induced acute gastric lesion in Wistar rats. *J Pharm Pharmacogn Res* 10(3): 508–516. https://doi.org/10.56499/jppres21.1336_10.3.508

Publisher's Note: All claims expressed in this article are solely those of the authors and do not necessarily represent those of their affiliated organizations, or those of the publisher, the editors and the reviewers. Any product that may be evaluated in this article, or claim that may be made by its manufacturer, is not guaranteed or endorsed by the publisher.